

Post-Burn Skin Deformities of the Face and Neck Region in Pediatric Patients: Single-Stage Treatment Using Collagen Elastin Matrix

Pediyatrik Olgularda Yanığa Bağlı Baş Boyun Bölgesi Deformitelerinin Kolajen-Elastin Matriks Kullanılarak Tek Aşamalı Cerrahi Tedavisi

Çağlayan Yağmur¹, Nuh Evin², Murat Sinan Engin¹, Tekin Şimşek¹, İsmail Küçüker¹, Ahmet Demir¹

¹Department of Plastic, Reconstructive and Aesthetic Surgery, Ondokuz Mayıs University School of Medicine, Samsun, Turkey

²Department of Plastic, Reconstructive and Aesthetic Surgery, Selçuk University School of Medicine Konya, Turkey

126

Abstract

Objective: Treating severe post-burn deformities of the face and neck region in pediatric populations is challenging because of technical difficulties (e.g., limited full thickness skin graft donor site, limited flap options, unavailability for expander placement) and increased donor site morbidity (e.g., related to flap and graft donor sites). In this study, we present the single-stage treatment of severe post-burn skin deformities of the face and neck region in pediatric patients using collagen-elastin matrix (Matriderm®) combined with partial thickness skin grafts.

Material and Methods: The total number of cases was eight (four females, four males), and the ages were between two and 11 years. All cases were operated on for only one region. Following the release of contractures and/or excision of wide excessive/unfavorable dermal scars, defects were reconstructed using collagen-elastin matrix (Matriderm®) combined with partial-thickness skin grafts. The final functional and aesthetic results were evaluated using photography and examination.

Results: The deformities were in the form of contractures and/or excessive dermal scarring. The involved regions were the face (n=3) and neck (n=5). The grafts yielded favorable plication and texture, and no recurrence of excessive dermal scarring was observed. All contractures healed unproblematically. Two patients were re-operated on for re-grafting caused by minor graft loss (5% and 12% of the total area, respectively).

Conclusion: In this study, we observed that collagen elastin matrix combined with partial-thickness skin grafts provides a favorable option for the treatment of pediatric late post-burn complications in the face and neck region with limited surgical options.

Keywords: Burns, collagen elastin matrix, pediatric burns, skin graft

Öz

Amaç: Pediyatrik olgularda yanığa bağlı ciddi baş boyun deformitelerinin düzeltilmesi, sınırlı tam kalınlıkta deri grefti verici sahası, sınırlı flep seçeneği ve ekspander yerleştirilmesindeki kısıtlılıklar gibi teknik zorluklar nedeniyle zorlayıcı olabilmektedir. Bu çalışmada pediyatrik olgularda yanığa bağlı oluşan baş boyun deformitelerinin kollajen elastin matriks (Matriderm®) kullanılarak tek aşamalı cerrahi tedavisine yönelik tecrübemiz aktarılmaktadır.

Gereç ve Yöntemler: Toplam olgu sayısı sekiz (dört kız, dört erkek) idi. Hastaların yaşları iki ile 11 arasında değişmekteydi. Tüm olgular sadece tek bir bölge için opere edildiler. Kontraktürlerin serbestlenmesi ve/veya geniş aşırı/uygunsuz skarların eksize edilmesini takiben oluşan doku eksiklikleri kollajen elastin matriks (Matriderm®) ile kombine şekilde uygulanan kısmi kalınlıkta deri grefti (KKDG) ile onarıldı. Sonuçların estetik ve fonksiyonel değerlendirilmesi muayene ve fotoğraflama ile yapıldı. Elde edilen fonksiyonel ve estetik sonuçlar fotoğraf ve muayene yöntemiyle değerlendirildi.

Bulgular: Deformiteler kontraktürler ve/veya aşırı dermal skarlaşma şeklindeydi. Üç hastada deformite yüzde, beş hastada deformite boyundaydı. Matriderm® üzerine uygulanan kısmi kalınlıkta deri greftleri uygun esneklik ve doku uyumuna ulaştı. Tüm kontraktürler problemsiz şekilde iyileşti. İki hasta minör greft kaybı (sırasıyla %5 ve %12) nedeniyle tekrar opere edildi.

Sonuç: Bu çalışmada elde ettiğimiz veriler doğrultusunda kollajen elastin matriks (Matriderm®) ile kombine şekilde uygulanan kısmi kalınlıkta deri greftinin, sınırlı cerrahi seçeneğin olduğu "yanık sonrası pediyatrik baş-boyun deformitelerinin rekonstrüksiyonunda" uygun bir seçenek olabileceğini ileri sürüyoruz.

Anahtar Sözcükler: Yanık, kollajen elastin matriks, pediyatrik yanık, deri grefti

Cite this article as: Yağmur Ç, Evin N, Engin MS, Şimşek T, Küçüker İ, Demir A. Post-Burn Skin Deformities of the Face and Neck Region in Pediatric Patients: Single-Stage Treatment Using Collagen Elastin Matrix. Turk J Plast Surg 2017; 25(3): 126-131.

This study was presented at the Turkish Society of Plastic Reconstructive and Aesthetic Surgeons Winter Symposium, 2-5 March 2017, Isparta, Turkey.

Bu çalışma, Türk Plastik Rekonstrüktif ve Estetik Cerrahi Derneği Kış Sempozyumu'nda sunulmuştur, 2-5 Mart 2017, Isparta, Türkiye.

Correspondence Author / Sorumlu Yazar: Çağlayan Yağmur, MD E-mail / E-posta: caglayanyagmur@gmail.com



Content of this journal is licensed under a Creative Commons Attribution-NonCommercial 4.0 International License.

Received / Geliş Tarihi: 23.11.2016

Accepted / Kabul Tarihi: 24.03.2017

INTRODUCTION

Burns are common and devastating injuries for the pediatric age group. The degree and extent of the burn injury determines the approach in treating post-burn skin deformities. Superficial burns in the pediatric age group tend to heal without complications and can usually be treated with analgesics, topical antibiotics, and dressings. However, surgical interventions are needed to resurface the defects in deep partial-thickness and full-thickness burns.^{1,2} Unlike superficial burns, deep dermal burns heal with complications such as excessive scarring (hypertrophic scars, keloids) and contracture bands.² These complications cause functional impediment, residual deformities, and emotional and psychosocial trauma in children.¹⁻⁴

Surgical treatment of such deformities hinges on two main objectives-releasing and/or excising scar bands and reconstructing the resultant defect.^{2,5} Depending on the depth and location of the defect, it can either be skin grafted, or resurfaced by a skin flap, and the former is almost universally applied unless the latter is deemed necessary.⁵ While skin flaps are accepted as the gold standard in functional reconstruction (especially around moving joints and within the growing body of the child), defects tend to be wide in children in whom flap donor sites are small. Local flaps from the vicinity of the contractures are the most straightforward and safe methods, and they are commonly employed as multiple Z-plasties or jumping-man flaps.⁵ In the scalp and thorax, an expander can be placed on the consistent bony surface to increase the amount and reach of the local flaps.^{2,5,6} In the upper extremities, distant flaps such as the groin flap or abdominal flap can be used at the cost of imposing a morbidity that can be hard to tolerate for a child. In confident hands, free tissue transfers remain as a single-stage procedure, and are the most effective method of reconstruction, and can be customized to the exact requirements of the defect; however, all but the most seasoned microsurgeons would need to make sure that all other options have expired before taking on the daunting task of performing microsurgery in the pediatric age group.

Enhancing the results of split-thickness skin grafts (STSG) has emerged as a third option. In this study, we are presenting our experience of joint application of collagen elastin matrix (Matriderm[®]; Dr. Suwelack AG, Billerbeck, Germany) and STSG in the face and neck region that were not amenable for flap reconstruction but at the same time would not be effectively treated by skin grafting alone.

MATERIAL AND METHODS

Eight patients who had been operated on for post-burn skin deformities on the face and neck region between 2012 and 2015 were included in this study. The authors were aware of the Code of Ethics of the World Medical Association (Declaration of Helsinki), which has been printed in the British Medical Journal (18 July 1964). Informed consent was obtained from the parents of each patient before surgery.

All patients underwent a single-stage treatment and were operated on at least eight months after the burn injury. Before surgery, patients' medical records were reviewed for age, sex, type of burn injury, previous treatment and surgical procedure, size and localization of affected area, and complaints of patients and their families. The photographs of skin deformities were taken with digital cameras. Informed consent from legal representatives was obtained for each patient before surgery.

During surgery, scar tissues and contracture bands were completely excised to the normal tissue. Meticulous hemostasis with bipolar cauterization and irrigation was then performed to prepare the recipient area. Full passive range of motion was re-established in the neck region to demonstrate the true functional extent of the resultant defect. Afterwards, pertinently tailored Matriderm[®] sheets (1 mm thick) were applied to the defect area and soaked with physiological saline (sodium chloride 0.9%) and covered with 0.3 mm thick unmeshed STSG harvested from the anterolateral thigh. The grafts were sutured in place and fixed via paraffin gauze tie-over dressings. The dressings were opened at the fourth postoperative day and followed by daily antibiotic ointment dressings. Custom pressure garments were prescribed after complete epithelialization was achieved.

Long-term follow-up and photography was done at the 12th postoperative month for each patient. Contraction rates of the grafts were determined via planimetric comparison of the surface areas of the defects prior to reconstruction and the healed grafts at the long-term follow up and were estimated in percentages. Scar analyses for both preoperative scars and postoperative outcomes were made via the Vancouver Scar Scale (VSS). Satisfaction of patients and their families was evaluated with the "satisfaction evaluation scale" (-1=poor, 0=no change, 1=moderate, 2=good, 3=very good).

Statistical Evaluation

Statistical Package for Social Sciences (SPSS Inc.; 16.0, Chicago, USA) was used for statistical analysis of all data. In the 95% confidence interval, a p-value of ≤ 0.05 was considered statistically significant. Patient satisfaction was assessed as a descriptive study and was analyzed by one-sample t-test. The paired t-test was used for both VSS and contraction rates of all scars. We evaluated the correlations among three variables (graft contraction rate, reduction of VSS score, and patient satisfaction) using Spearman's correlation.

RESULTS

Four of the patients were female, and four were male. The age range was two to 11 years with a mean of 5.5 years. Five of the regions were on the neck and three were on face. The causative agent was scalding in three patients and contact burn in five patients. Three of the patients had scar contractures, three of them had excessive dermal scarring (EDS), and two of them had both. Five patients with EDS (all in the neck region) were previously treated by non-surgical modalities and reported no benefit from compression garments and repetitive application of intralesional corticosteroids.

One of the three patients with neck burns had flexion contracture with 30-degree extension limitation of the neck, and the other two had unsightly scars and minor contracture bands. The three patients with facial burns had ectropion of the lower eyelid, lower distortion of the oral commissure, and/or short alar flaring. At the same time, these patients were suffering from abnormal facial appearance. Two patients had previously undergone STSG surgery, while the other six were allowed to heal by secondary intention alone. The detailed patient data are summarized in Table I. The main complaint was unsightly scars. Severe itching was also common in EDS lesions.

Postoperatively, there were no major complications associated with graft take, such as hematoma, seroma, infection, and/

or complete graft loss. In two patients, partial loss (5% and 12%, respectively) of the grafts occurred, and they were re-grafted in another session.

At the first-year follow-up, all scars were level with the surrounding uninvolved skin and evenly vascularized and pigmented (Figure 1-3). The mean VSS scores at the 12th postoperative month (3.6 ± 0.91) were significantly ($p < 0.05$) lower than preoperative scores (10.25 ± 1.38) (Table II).

All contractures were virtually eliminated by the end of the first year after the surgery. Ectropion in two patients with facial burns was treated with simultaneous canthopexy, and relapse was not observed (Figure 3).

Table I. Patient medical records

Patient number	Age/ Sex	Location	Type of burn	Type of burn complication	Type of the deformity and complaints	Previous treatment	Size of affected area (cm ²)	Final area after treatment (cm ²)	Contraction rate (%)
1	3 F	Neck	Contact	EDS*	Unsightly scar, itching	Secondary***	40	37	7.5
2	7 F	Neck	Scald	EDS, C**	Contracture due to scar, unsightly scar, itching	Secondary	80	75	6.25
3	3 M	Neck	Scald	EDS	Unsightly scar, itching	Secondary	27	24	11.1
4	2 F	Face	Contact	C	Ectropion, distortion of oral commissure, short alar flaring	STSG****	32	28	12.5
5	2 F	Face	Scald	C	Ectropion, distortion of oral commissure	Secondary	22	19	13.6
6	11 M	Face	Contact	C	Unsightly scar on malar region, distortion of oral commissure	Secondary	20	17	15
7	10 M	Neck	Contact	EDS	Unsightly scar, itching	Secondary	62	55	11.2
8	6 M	Neck	Contact	EDS	Unsightly scar and minor contracture	STSG	32	29	9.3

*EDS: excessive dermal scarring; **C: contracture band; ***Secondary: healing by secondary intention; ****STSG: split-thickness skin graft

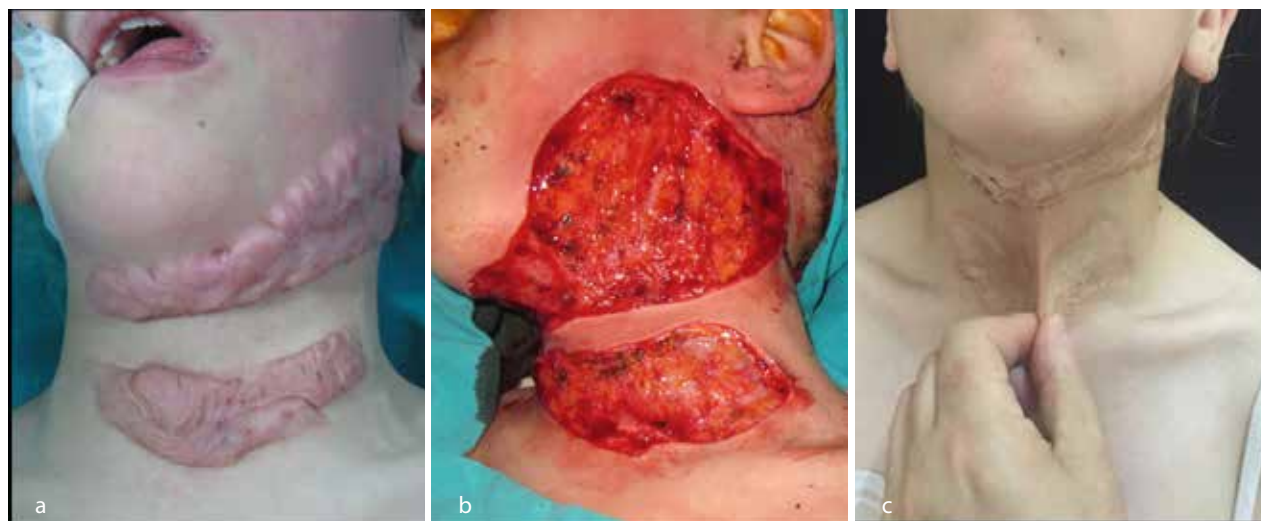


Figure 1. a-c. A Seven-year-old girl with a scald burn injury to her neck. At 13 months after injury, she presented with two bands of excessive dermal scarring (a) with severe itching. Scars were excised, and the defect area was resurfaced with split-thickness skin grafts applied over Matriderm® (b). On the right side (c) is the two-year postoperative result. Although she has some texture problem with the graft, there is good pliability of the reconstructed region, and no major recurrence of excessive dermal scarring has occurred

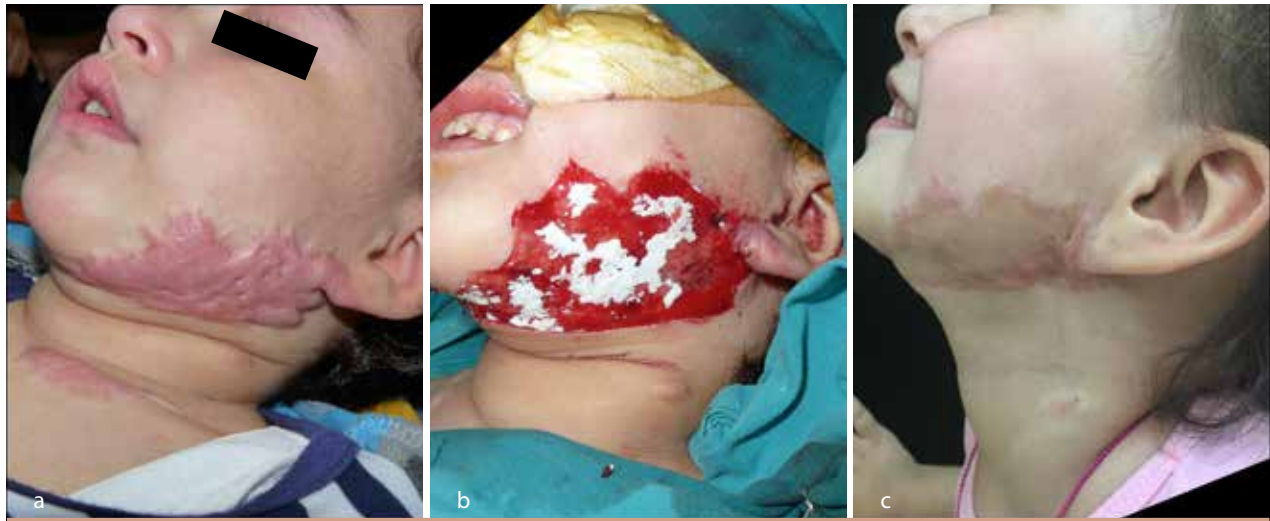


Figure 2. a-c. A three-year-old girl with a scald burn to her neck. Eleven months post-injury, she presented with an excessive dermal scarring lesion that also caused severe itching (a). This condition was reported to be impeding the child's social development. Conservative measures failed to yield satisfactory results, and excision was planned. Please note that Matriderm® soaks up blood and allows nutrition of the overlying skin graft (b). Postoperative one-year result (right side). The symptoms faded, and she had no remarkable recurrence of excessive scarring (c)

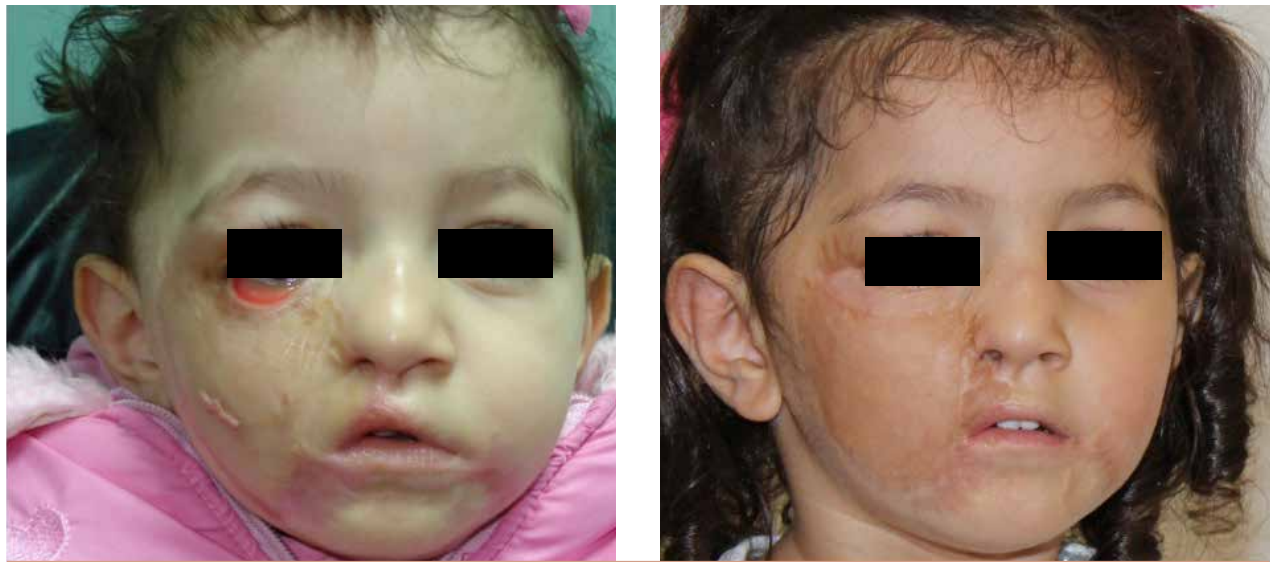

Figure 3. a, b. The girl was one year old when contact with a hot ironer inflicted a burn injury. She was initially treated by split-thickness skin graft. However, late contraction of the graft imposed ectropion of the lower eyelid and contracture of the lip (a). After total excision of the graft and release of the contractures influencing the mouth, the resultant defect was resurfaced with a combination of Matriderm® and split-thickness skin graft. Simultaneously, the ectropion was corrected by tarsal strip canthopexy. After this operation, there was a small healing problem in the lower eyelid region. The area was again reconstructed using the Matriderm combination. The two-year postoperative result is shown on the right (b). Although there is some inconsistency with the color, no further late contractures of the grafts occurred, and there were favorable results with the correction of the eyelid and oral commissure contractures

The average surface areas of the defects preoperatively and at one year after being grafted with Matriderm were 39.3 cm² and 35.5 cm², respectively, with a statistically significant contraction rate of 9.6% ($p < 0.05$) (Table I).

The average patient satisfaction rate was 1.9 (good satisfaction). According to the one-sample t-test, there was a statistically sig-

nificant difference in average patient satisfaction and test value (0=no change in satisfaction). These patients were significantly satisfied with the surgical outcome ($p < 0.05$) (Table III).

We evaluated the correlations among three variables (graft contraction rates, reduction of VSS scores, and patient satisfaction) using Spearman's correlation. There was a nega-

Table II. Pre- and Post-operative Vancouver Scar Scale Scores, * at the 12th postoperative month

Patient number	Preoperative VSS Score	Postoperative VSS Score*	Reduction of VSS Score
1	11	3	8
2	11	5	6
3	11	4	7
4	7	2	5
5	10	3	7
6	10	4	6
7	11	4	7
8	11	4	7

VSS: Vancouver Scar Scale Scores

Table III. Patient satisfaction rate scores

Patient number	Satisfaction score	Improvement degree
1	2	Good
2	1	Moderate
3	2	Good
4	1	Moderate
5	2	Good
6	3	Good
7	1	Good
8	3	Good

tive inverse relationship (73.3%) between contraction rates and the reduction of VSS scores, and a positive relationship (82.2%) between the reduction of VSS scores and patient satisfaction.

DISCUSSION

In our study, Matriderm® and STSG were combined for the treatment of late post-burn deformities and contractures involving the face and neck in a single-step procedure in pediatric patients. We resurfaced defects that would otherwise necessitate full-thickness skin grafts FTSGs or distant/free flaps while inflicting the donor site morbidity of STSGs alone.

Matriderm® is a dermal substitute composed of bovine dermal collagen I, III, V and elastin with no cross-linking, and it can be combined with STSGs for one-stage reconstruction of full-thickness skin defects as a possible alternative to two-stage substitutes.⁷⁻¹⁰ Its thinness (1 mm) allows plasma imbibition to reach the graft and ensures graft take while providing a thicker and more pliable dermal infrastructure. Ryssal et al.⁷ and Demircan et al.¹¹ investigated its use in conjunction with STSGs in a single-stage procedure and reported that its use yielded better functional and cosmetic results than an application of STSG alone. As far as pediatric cases are concerned, in whom burn wounds and scars tend to be large while donor sites are still small, this is of even greater importance.

Theoretically, burn healing can be optimized with nonoperative methods such as custom-made elastic pressure garments, rigid facial masks, silicone gel sheeting, functional splinting, intensive physical therapy, radiotherapy, laser treatment, topical applications of vitamin E, and topical or intralesional injection of steroids to prevent EDS.^{12,13} While most of these methods are hard to tolerate, especially for the pediatric population, it is advocated that nonoperative treatment options should be utilized before surgical intervention because they are reported to improve surgical outcome even if they do not resolve the problem altogether.¹⁴ In our series of patients, nonoperative treatments except for radiotherapy, which is contraindicated in children because of high carcinogenic potential, were attempted in all five patients with EDS with varying degrees of success.

Given the difficulty in cooperation with youngsters, the evaluation of preoperative and postoperative scars was made using VSS instead of POSAS (Patient and Observer Scar Assessment Scale). The VSS universally assesses scars caused by burns in four categories (vascularity, pigmentation, pliability, and height of scar).¹⁵ The average VSS score at the 12th postoperative month (3.6±0.91) was significantly (p<0.05) lower than the preoperative score (10.25±1.38). VSS analyses also showed that swelling and stiffness of the scars were significantly more improved than other parameters.

In our series, the combination of Matriderm® and STSG provided good cosmesis by minimizing contractures and enhancing skin elasticity in the treatment of pediatric post-burn head and neck skin deformities. According to our literature search, the combination of STSG and dermal substitutes has not been reported for this purpose elsewhere.

CONCLUSION

We believe that dermal substitutes, especially Matriderm®, are a convenient tool for overcoming the limitations of reconstructive options for pediatric post-burn skin deformities in the head and neck region when used in combination with STSGs. Thus, defects that would otherwise require FTSGs or flap surgery can be resurfaced by STSGs with favorable functionality and cosmesis.

Ethics Committee Approval: Authors declared that the research was conducted according to the principles of the World Medical Association Declaration of Helsinki "Ethical Principles for Medical Research Involving Human Subjects" (amended in October 2013).

Informed Consent: Written informed consent was obtained from the parents of the patients who participated in this study.

Peer-review: Externally peer-reviewed.

Author Contributions: Concept - Ç.Y.; Design - Ç.Y., N.E.; Supervision - A.D.; Resource - A.D.; Materials - A.D.; Data Collection and/or Processing - Ç.Y., N.E., M.S.E., T.Ş., İ.K.; Analysis and/or Interpretation - İ.K., T.Ş.; Literature Search - Ç.Y., N.E.; Writing Manuscript - Ç.Y., N.E.; Critical Reviews - M.S.E., A.D.

Conflict of Interest: No conflict of interest was declared by the authors.

Financial Disclosure: The authors declared that this study has received no financial support.

Etik Komite Onayı: Yazarlar çalışmanın World Medical Association Declaration of Helsinki "Ethical Principles for Medical Research Involving Human Subjects" (amended in October 2013) prensiplerine uygun olarak yapıldığını beyan etmişlerdir.

Hasta Onamı: Yazılı hasta onamı bu çalışmaya katılan hastaların ailelerinden alınmıştır.

Hakem Değerlendirmesi: Dış bağımsız.

Yazar Katkıları: Fikir - Ç.Y.; Tasarım - Ç.Y., N.E.; Denetleme - A.D.; Kaynaklar - A.D.; Malzemeler - A.D.; Veri Toplanması ve/veya İşlemesi - Ç.Y., N.E., M.S.E., T.Ş., İ.K.; Analiz ve/veya Yorum - İ.K., T.Ş.; Literatür Taraması - Ç.Y., N.E.; Yazıyı Yazan - Ç.Y., N.E.; Eleştirel İnceleme - M.S.E., A.D.

Çıkar Çatışması: Yazarlar çıkar çatışması bildirmemişlerdir.

Finansal Destek: Yazarlar bu çalışma için finansal destek almadıklarını beyan etmişlerdir.

REFERENCES

- Birchenough SA, Gampper TJ, Morgan RF. Special considerations in the management of pediatric upper extremity and hand burns. *J Craniofac Surg* 2008; 19(4): 933-41. [\[CrossRef\]](#)
- Kung TA, Gosain AK. Pediatric facial burns. *J Craniofac Surg* 2008; 19(4): 951-9. [\[CrossRef\]](#)
- Liber JM, List D, Van Loey NEE, Kef S. Internalizing problem behavior and family environment of children with burns: a Dutch pilot study. *Burns* 2006; 32(2): 165-71. [\[CrossRef\]](#)
- Kent L, King H, Cochrane R. Maternal and child psychological sequelae in paediatric burn injuries. *Burns* 2000; 26(4): 317-22. [\[CrossRef\]](#)
- Cartotto R, Cicuto BJ, Kiwanuka HN, Bueno EM, Pomahac B. Common postburn deformities and their management. *Surg Clin North Am* 2014; 94(4): 817-37. [\[CrossRef\]](#)
- Ashab Yamin MR, Mozafari N, Mozafari M, Razi Z. Reconstructive surgery of extensive face and neck burn scars using tissue expanders. *World J Plast Surg* 2015; 4(1): 40-9.
- Ryssel H, Gazyakan E, Germann G, Ohlbauer M. The use of Matriderm in early excision and simultaneous autologous skin grafting in burns-pilot study. *Burns* 2008; 34(1): 93-7. [\[CrossRef\]](#)
- Atherton DD, Tang R, Jones I, Jawad M. Early excision and application of Matriderm with simultaneous autologous skin grafting in facial burns. *Plast Reconstr Surg* 2010; 125(2): 60e-1e. [\[CrossRef\]](#)
- van Zuijlen PP, van Trier AJ, Vloemans JF, Groenevelt F, Kreis RW, Middelkoop E. Graft survival and effectiveness of dermal substitution in burns and reconstructive surgery in a one-stage grafting model. *Plastic Reconstr Surg* 2000; 106: 615-23. [\[CrossRef\]](#)
- Haslik W, Kamolz LP, Nathschläger G, Andel H, Meissl G, Frey M. First experiences with the collagen-elastin matrix Matriderm as a dermal substitute in severe burn injuries of the hand. *Burns* 2007; 33(3): 364-8. [\[CrossRef\]](#)
- Demircan M, Cicek T, Yetis MI. Preliminary results in single-step wound closure procedure of full-thickness facial burns in children by using the collagen-elastin matrix and review of pediatric facial burns. *Burns* 2015; 41(6): 1268-74. [\[CrossRef\]](#)
- Tredget EE, Nedelec B, Scott PG, Ghahary A. Hypertrophic scars, keloids, and contractures: the cellular and molecular basis for therapy. *Surg Clin North Am* 1997; 77(3): 701-30. [\[CrossRef\]](#)
- Allison KP, Kiernan MN, Waters RA, et al. Pulsed dye laser treatment of burn scars. Alleviation or irritation? *Burns* 2003; 29(3): 207-13. [\[CrossRef\]](#)
- Harrison CA, MacNeil S. The mechanism of skin graft contraction: an update on current research and potential future therapies. *Burns* 2008; 34(2): 153-63. [\[CrossRef\]](#)
- Sullivan T, Smith J, Kermod J, McIver E, Courtemanche DJ. Rating the burn scar. *J Burn Care Rehabil* 1990; 11(3): 256-60. [\[CrossRef\]](#)