

Severe Hand Injuries Caused by a Mole Gun

Köstebek Tabancasının Neden Olduğu Ciddi El Yaralanmaları

Serdar Düzgün¹, Alpay Duran²

¹Department of Plastic and Reconstructive Surgery, Gülhane Training and Research Hospital, Ankara, Turkey

²Department of Plastic and Reconstructive Surgery, Şanlıurfa Training and Research Hospital, Şanlıurfa, Turkey

120

Abstract

Objective: Injuries by mole guns differ from other firearm injuries primarily because they are close-range, low-energy injuries that are highly contaminated owing to contact with contaminated surfaces and the presence of numerous residual foreign bodies within the wound. The aim of this article is to share our surgical experience regarding the repair of severe hand injuries caused by mole guns.

Material and Methods: This retrospective study included 11 patients with hand injuries. Data obtained about the patients, including age, gender, dominant or non-dominant hand, injuries to all vital structures, and reconstructive procedures were assessed, categorized, and recorded.

Results: Ten patients had defects in one or several common digital branches of the median nerve in areas ranging from the distal part of the carpal tunnel to the distal palmar crease. All patients had flexor and extensor tendon injuries in all fingers except for the first finger. Reconstruction of soft tissue and skin defects was carried out with an interpolation flap planned from a random-based subpectoral-paraumbilical region in five patients, a SCIA-based groin flap in four patients, a reverse-radial forearm flap in one patient, and an adipofascial flap planned from the forearm in one patient.

Conclusion: Mole gun injuries typically include all structures of the hand, and repair procedures involve every anatomic structure of the hand. An early and effective surgical operation followed by prolonged and effective physical therapy protocols is vital for regaining the full spectrum of hand functions.

Keywords: Mole gun, hand injury, flap, reconstruction, tendon, nerve

Öz

Amaç: Köstebek tabancasıyla yaralanan tüm hastaların diğer ateşli silah yaralanmalarından farkı, yaralanmanın çok yakın mesafeden gerçekleşmesi, düşük enerjili olması, çok sayıda rezidüel yabancı cisim içermesi ve kontamine alanla temas etmesinden dolayı kirli bir yaralanma olmasıdır. Bu çalışmanın amacı, köstebek tabancasıyla gelişen el yaralanmalarında klinik deneyimlerimizin paylaşılmasıdır.

Gereç ve Yöntemler: Bu retrospektif çalışmaya 11 hasta dâhil edildi. Hastalar hakkında elde edilen veriler, yaş, cinsiyet, baskın veya baskın olmayan eli içermesi, tüm hayati yapılarda oluşan yaralanmalar, rekonstrüktif prosedürler değerlendirildi, sınıflandırıldı ve kaydedildi.

Bulgular: On hastada karpal tünelin distalinden distal palmar krize kadar olan alanda median sinirin common dijital sinir dallarının birinde/birkaçında defekt olduğu izlendi. Hastaların hepsinde birinci parmak haricinde diğer parmaklarda fleksör ve ekstansör tendon yaralanmaları mevcuttu. Hastaların mevcut yumuşak doku ve cilt defektlerinin rekonstrüksiyonu için beş hastada random bazlı subpektoral-paraumbilikal bölgeden planlanan interpolasyon flebi, dört hastada SCIA bazlı groin flebi, bir hastada ters-radial ön kol flebi flebi, bir hastada ön koldan planlanan adipofasial flep uygulandı.

Sonuçlar: Köstebek tabancasıyla yaralanmalar ileri derecede el hasarı ile beraber seyretmektedir. Yaralanma sonucu hasar, elin tüm yapılarını içine alır ve onarım tüm anatomik yapıları ilgilendirir. Erken ve etkili bir cerrahi ve takiben uzun soluklu ve etkili fizik tedavi protokollerinin elin fonksiyonel geri dönüşümü için mutlak olduğunu düşünmekteyiz.

Anahtar Sözcükler: Köstebek tabancası, el yaralanması, flep, rekonstrüksiyon, tendon, sinir

Cite this article as: Düzgün S, Duran A. Severe Hand Injuries Caused by a Mole Gun. Turk J Plast Surg 2017; 25(3): 120-125.

Correspondence Author / Sorumlu Yazar: Alpay Duran, MD E-mail / E-posta: dr.alpayduran@hotmail.com



Content of this journal is licensed under a Creative Commons Attribution-NonCommercial 4.0 International License.

Received / Geliş Tarihi: 22.11.2016
Accepted / Kabul Tarihi: 10.05.2017

INTRODUCTION

A mole gun is a simple but effective firearm long used by farmers and agricultural workers to kill animals such as moles. This weapon has a sensitive trigger mechanism and it works by rapid, high-velocity ejection of buckshot from the barrel after gunpowder ignition.^{1,2} In hand injuries caused by mole guns, the victims inadvertently suppose that the gun has already fired and are injured by the shot when they handle the gun because of an overly sensitive trigger mechanism. Hand injuries caused by mole guns are characterized by large tissue defects. Moreover, this dangerous weapon leads to both functional and structural dysfunction of the hand. Hand reconstruction following these injuries is particularly difficult, requiring multiple operations at considerable cost.³ Injuries by mole guns differ from other firearm injuries primarily because they are close-range, low-energy injuries that are highly contaminated owing to contact with contaminated surfaces and the presence of numerous residual foreign bodies within the wound. Reconstruction of these injuries involves time-consuming, multi-staged procedures

often with unsatisfactory results. The aim of this article is to share our surgical experience regarding the repair of such severe hand injuries.

MATERIAL AND METHODS

The study was conducted in compliance with the Helsinki Declaration and after informed consent was obtained from every patient. This retrospective study included 11 patients (eight males and three females; average age: 42.5 years; range: 23 to 70 years) with hand injuries. All injuries were inadvertent self-inflicted gunshot wounds from very close range while handling a mole gun.

Data obtained about the patients, including age, gender, dominant or non-dominant hand, and injuries to all vital structures, were assessed, categorized, and recorded. All hand injuries had an entry point on the palmar surface and an exit point on the dorsal surface accompanied by tendon, vessel, nerve, bone, and soft tissue injuries, and skin defects of various sizes (Figure 1-3)

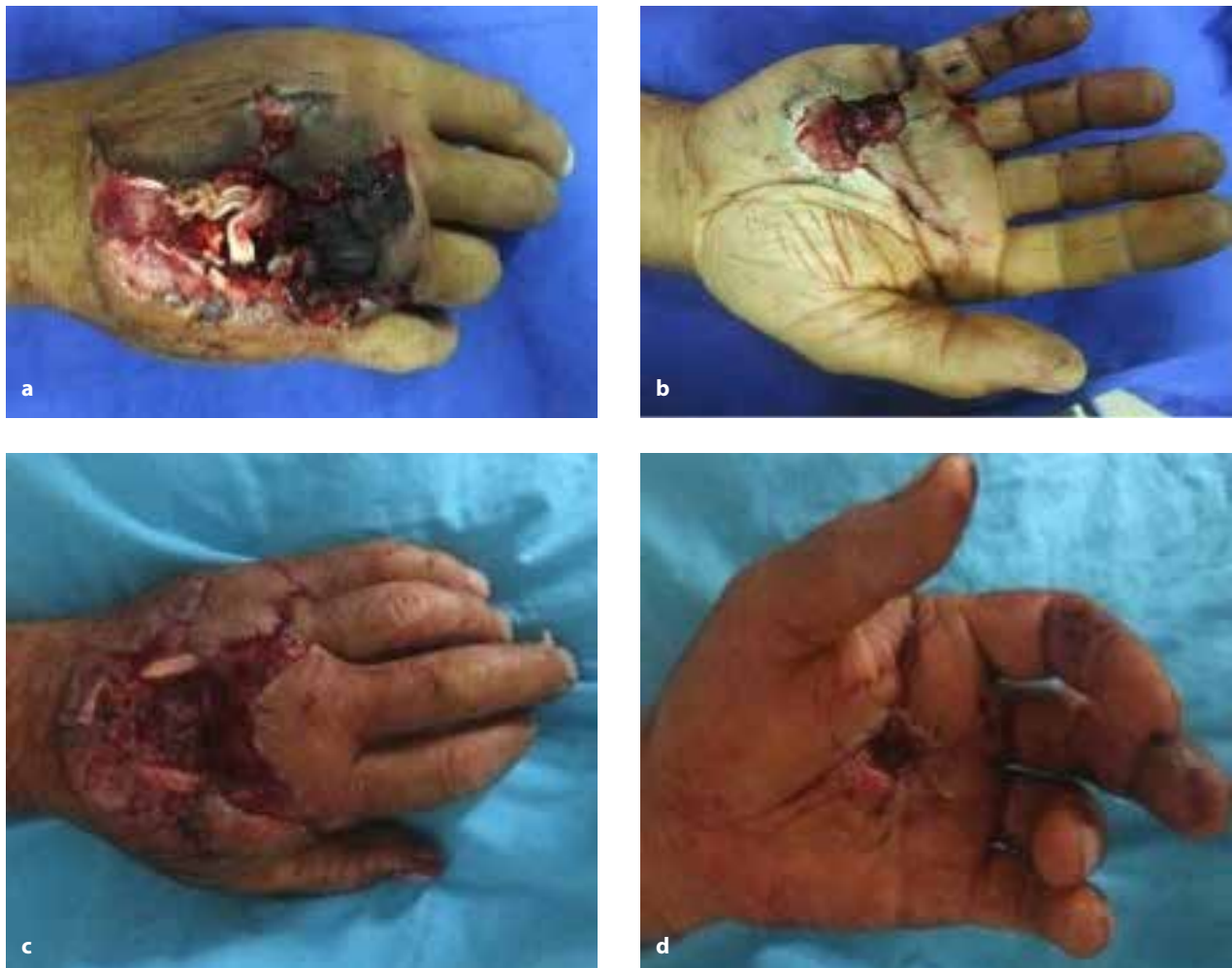

Figure 1. a-d. (a-b) Case 1, dorsal and volar aspect of the right hand with 4th flexor digitorum superficialis tendon defect, 4th metacarp defect, and 3rd common branch of median nerve defect. (c-d) Case 9, dorsal and volar aspect of the left hand with 3rd flexor digitorum superficialis tendon defect, 3rd metacarp defect, and 3rd common branch of median nerve defect

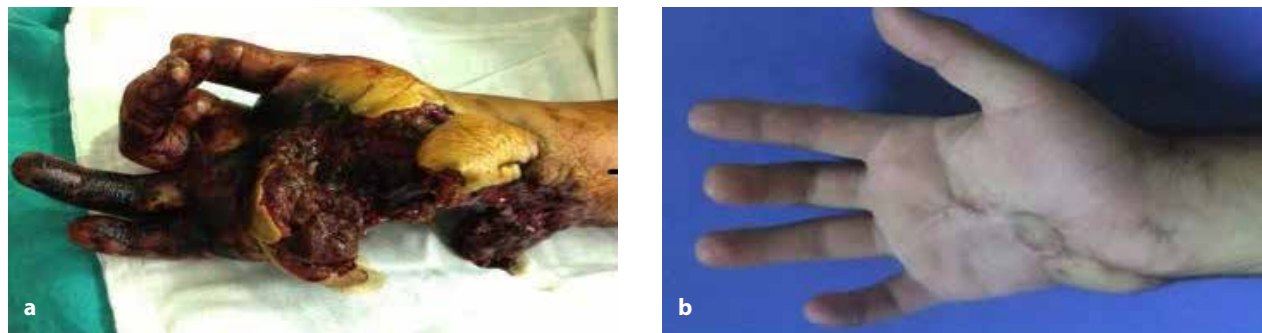


Figure 2. a, b. (a) Case 2, volar aspect of the injured right hand with 3rd and 4th flexor digitorum superficialis and profundus tendon defect, 3rd and 4th extensor digitorum comminis and extensor digiti minimi tendon defect (distal of the ulna), 4th and 5th metacarp, os triquetrum, pisiforme, os capitatum, os hamatum defect, and 3rd common branch of the median nerve motor branch of the ulnar nerve. (b) Late postoperative dorsal view of the hand after 6 months

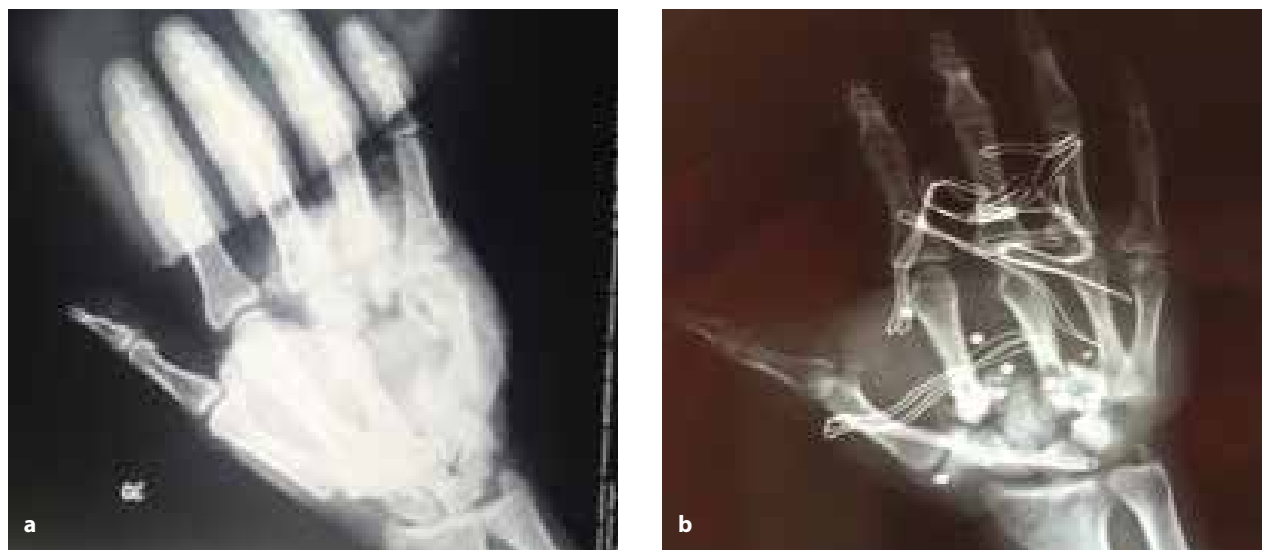

Figure 3. a, b. (a) Preoperative x-ray of the 4th metacarpal defect. (b) Preoperative x-ray of the carpometacarpal bone defect with foreign bodies

Nine patients had right hand injuries and two had left hand injuries. Eight patients were injured in the dominant hand. The injured patients were first assessed in the emergency department. Because all wounds presented contaminated blast injuries, their management in the emergency department included careful irrigation and debridement in order to remove necrotic material. Wounds were closed with a single layer of nitrofurazone and rifampicin-containing gauze. All patients received appropriately positioned splints to maintain stability and preserve circulation. None of the patients had circulatory complications. Because all wounds were considered contaminated, parenteral broad-spectrum first-generation cephalosporin and metronidazole treatment was begun. Initial care was followed by surgical reconstruction during the acute period. All patients received their initial operation within 24 to 72 hours (average: 42 hours) of the gunshot wound.

RESULTS

Nine patients had defects in one or several common digital branches of the median nerve in areas ranging from the dis-

tal part of the carpal tunnel to the distal palmar crease. One patient had defects involving the sensory branches of both ulnar and median nerves. One patient had no nerve injury. The patient data are summarized in Table I.

Autologous iliac bone graft was harvested and fixed with a plate-screw to reconstruct bone defects. Functional arthrodesis (with plate-screw of the bone graft) was applied to carpometacarpal joint defects in five patients. Functional arthrodesis with plate-screw was applied for defects in the 4th and 5th metacarpal bones, carpal bones, and the distal ulna in one patient. In the remaining patients, defects in the mid-neck region of the metacarpal bone were repaired with bone graft using plate-screw.

The palmaris longus tendon was generally used for reconstruction of tendon defects. The flexor digitorum superficialis tendon of the fourth finger (which is conventionally used for tendon transfer) was not preferred because it was defective or injured in these patients. In patients having no palmaris longus tendon, the plantaris tendon was used as the donor

Table I. Patient data

	Age	Injured hand	Dominant hand	Tendon defect	Nerve defect	Bone defect	Skin and soft-tissue defect	Reconstructive procedure
1	23	Right	Right	4 th FDS	3 rd Common branch of median nerve	4 th Metacarp	Palmar region 3×1 cm Dorsal region 4×4 cm	Random-based interpolation flap
2	26	Right	Right	4-5 FDP-FDS 4-5 EDC 5 th EDM	3 rd Common branch of median nerve motor branch of ulnar nerve	Distal of ulna 4 th 5 th Metacarp os triquetrum-psiforme capitatum-hamatum	Palmar region 4×3 cm Dorsal region 4×3 cm	Random-based interpolation flap
3	32	Right	Right	5 th FDS-FDP 5 th EDC	-	5 th Metacarp	Palmar region 2×2 cm Dorsal region 5×4 cm	SCIA-based groin flap
4	33	Right	Right	2 nd FDS 2 nd EDC-EIP	2 nd Common branch of median nerve	2 nd - 3 rd Metacarp	Palmar region 2×2 cm Dorsal region 6×3 cm	Reverse radial forearm flap
5	37	Left	Right	4 th FDS-FDP	3 rd Common branch of median nerve	4 th Metacarp	Palmar region 2×1 cm Dorsal region 5×4 cm	Random-based interpolation flap
6	41	Right	Right	3 rd FDP	2 nd Common branch of median nerve	3 rd Metacarp	Palmar region 3×1 cm Dorsal region 5×5 cm	SCIA-based groin flap
7	45	Right	Right	4 th FDS-FDP 4 th EDC	3 rd Common branch of median nerve	3 rd - 4 th Metacarp	Palmar region 2×1 cm Dorsal region 3×3cm	Random-based interpolation flap
8	49	Right	Right	2 nd FDP 3 rd FDS-FDP 3 rd EDC	2 nd - 3 rd Common branch of median nerve	2 nd - 3 rd Metacarp	Palmar region 2×1 cm Dorsal region 4×4 cm	SCIA-based groin flap
9	54	Left	Right	3 FDP	3 rd Common branch of median nerve	3 rd Metacarp	Palmar region 3×1 cm Dorsal region 5×3 cm	SCIA-based groin flap
10	58	Right	Left	3 FDS-FDP	3 rd Common branch of median nerve	3 rd - 4 th Metacarp	Palmar region 3×2 cm Dorsal region 6×4 cm	Adipofascial turnover flap
11	70	Right	Right	2-3 FDS-FDP	3 rd Common branch of median nerve	2 nd Metacarp	Palmar region 2×1 cm Dorsal region 5×3 cm	Random-based interpolation flap

FDP: flexor digitorum profundus; FDS: flexor digitorum superficialis; EDC: extensor digitorum communis; EIP: extensor indicis proprius; SCIA: superficial circumflex iliac artery

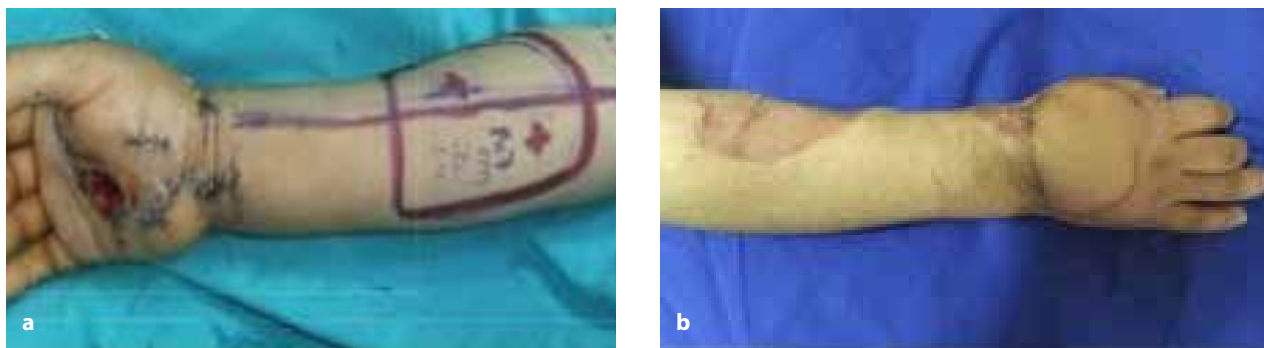


Figure 4. a, b. (a) Case 4, preoperative markings of reverse radial forearm flap. (b) Late postoperative view of the flap after 6 months

tendon. Because one patient lacked the palmaris longus and plantaris tendons, the extensor tendon of the 3rd toe was used. That patient was re-operated on the 6th day post injury due to tendon rupture, which was reconstructed using a fascia lata tendon graft.

Sural nerve graft was used for the reconstruction of median and ulnar nerve defects. In postoperative 6th month, repeat intra-operative examination of five patients revealed that the nerve grafts remained in excessively fibrotic tissues, and thus neurolysis procedure was performed, which proved unsatisfactory.

Reconstruction of soft tissue and skin defects was carried out with an interpolation flap planned from the random-based subpectoral-paraumbilical region in five patients, a SCIA-based groin flap in four patients, a reverse-radial forearm flap (Figure 4) in one patient, and an adipofascial flap planned from the forearm in one patient. None of the patients experienced a problem regarding flap circulation, and no flaps were lost. Reconstruction with a free flap was not planned in any of these patients owing to the high probability of diffuse endothelial injury-thrombus because the recipient vessels were in the injury zone. Furthermore, reconstruction of the defective

region with a more reliable flap together with early physiotherapy hastened return to work. Due to strict adherence to the rules of urgent debridement and administration of parenteral wide-spectrum antibiotics, none of our patients has suffered an infection to date.

DISCUSSION

Injuries by a mole gun are low-energy injuries, but they differ from other firearm injuries in that they occur at close-range and are contaminated wounds.¹⁻⁴ The most important feature of mole gun injuries is the high rate of tendon, nerve, bone, and extensive soft tissue-skin defects as a result of the close-range nature of the injury.⁵ After such an injury, multi-stage reconstruction is needed to regain hand functionality.

All patients in our clinic underwent surgery within 72 hours of their injury. All fractures were repaired with plate and screw, while bony defects were repaired using bone grafts in the same session. Although delayed graft applications are preferable in contaminated wounds, intensive and effective antibiotic use along with early use of bone grafting in the same operative session prevented infection and bone loss. Furthermore, coupled with early physiotherapy, this method proved beneficial in ensuring the patient's early return to normal lifestyle.⁶

In this study, reconstruction of bone and soft tissue defects was performed much earlier than in previous studies.^{1,3} In addition, bone, tendon, nerve, and soft tissue-skin defects were repaired in the same operative session. Although injuries to a substantial number of significant structures of the hand produce unsatisfactory results to some extent, performing appropriate reconstructive steps in the shortest time period is of utmost importance.

Reconstruction using a free flap was not planned in any of the patients, since their injuries were blast and burn injuries that involved the vessels of the recipient region. In addition, because the region was subjected to high-energy trauma, there was diffuse endothelial injury with a high probability of thrombus formation due to severe edema that developed on the 2nd day. Local flaps and interpolation flaps are preferred for repair of skin and soft tissue defects, because they are felt to be safer.⁷ No complications developed in patients in whom local and interpolation flaps were applied. A delay procedure (beginning on the 9th day) was performed in patients receiving an interpolation flap, and the flaps were detached on the 15th day.

In summary, our treatment protocol for mole gun injuries includes urgent surgical debridement and administration of parenteral broad-spectrum antibiotics due to the contaminated nature of these wounds. They usually occur in persons working in farms, fields, or gardens in rural areas. Victims sometimes suffer irreversible disabilities and may need long-term rehabilitation. Moreover, severe infections may result owing to the contaminated nature of these injuries. Therefore, urgent irrigation of the wound, and debridement of all necrotic tissue, buckshot, and foreign and contaminated objects is critical in preventing infections before proceeding with reconstruction.^{8,9}

Patients usually undergo surgery within 72 hours for closure of bone, tendon, nerve, and soft tissue-skin defects. Repair of all available defects is completed in the same session, and the patients are admitted to hospital for a prolonged period (usually 21 days) and receive active and passive exercise programs, paraffin baths, hot and cold baths, and anti-edema therapy. This is followed by active and passive exercise programs at home for three months.

CONCLUSION

Injuries by mole gun are characterized by severe hand injuries that differ from other firearm injuries primarily because they are close-range, low-energy injuries that are highly contaminated. Such injuries typically affect all structures of the hand, and repair procedures involve every anatomic structure of the hand. An early and effective surgical operation followed by prolonged and effective physical therapy protocols is vital for regaining the full spectrum of hand functions.

Ethics Committee Approval: Authors declared that the research was conducted according to the principles of the World Medical Association Declaration of Helsinki "Ethical Principles for Medical Research Involving Human Subjects" (amended in October 2013).

Informed Consent: Written informed consent was obtained from the patients for the publication of this study.

Peer-review: Externally peer-reviewed.

Author contributions: Concept - S.D.; Design - S.D.; Supervision - S.D., A.D.; Resource - S.D., A.D., X; Materials - S.D.; Data Collection and/or Processing - S.D., A.D.; Analysis and/or Interpretation - A.D.; Literature Search - S.D., A.D.; Writing Manuscript - S.D.; Critical Reviews - S.D., A.D.

Conflict of Interest: No conflicts of interest were declared by the authors.

Financial Disclosure: The authors declared that this study has received no financial support.

Etik Komite Onayı: Yazarlar çalışmanın World Medical Association Declaration of Helsinki "Ethical Principles for Medical Research Involving Human Subjects", (Ekim 2013'te gözden geçirilmiş) prensiplerine uygun olarak yapıldığını beyan etmişlerdir.

Hasta Onamı: Yazılı hasta onamı bu çalışmaya katılan hastalardan alınmıştır.

Hakem Değerlendirmesi: Dış bağımsız.

Yazar Katkıları: Fikir - S.D.; Tasarım - S.D.; Denetleme - S.D., A.D.; Kaynaklar - S.D., A.D.; Malzemeler - S.D.; Veri Toplanması ve/veya İşlemesi - S.D., A.D.; Analiz ve/veya Yorum - A.D.; Literatür Taraması - S.D., A.D.; Yazıyı Yazan - S.D.; Eleştirel İnceleme - S.D., A.D.

Çıkar Çatışması: Yazarlar çıkar çatışması bildirmemişlerdir.

Finansal Destek: Yazarlar bu çalışmada finansal destek alınmadığını bildirmişlerdir.

REFERENCES

1. Keskin M, Beydes T, Tosun Z, Savaci N. Close range gunshot injuries of the hand with the "mole gun". *J Trauma* 2009; 67(1): 139-42. [\[CrossRef\]](#)
2. Uner HB, Gurpınar SS, Cakir I. Mole gun-an unusual firearm, a case note. *Forensic Sci Int* 2001; 118: 83-5. [\[CrossRef\]](#)
3. Demirci S, Gunaydin G, Dogan KH, Erkol Z. Deaths caused by mole guns: three case reports. *Int J Legal Med* 2008; 122: 323-5. [\[CrossRef\]](#)
4. Fackler ML, Burkhalter WE. Hand and forearm injuries from penetrating projectiles. *J Hand Surg Am* 1992; 17A: 971-5. [\[CrossRef\]](#)
5. Wilson RH. Gunshots to the hand and upper extremity. *Clin Orthop Relat Res* 2003; 408: 133-44. [\[CrossRef\]](#)
6. Komurcu M, Alemdaroglu B, Kurklu M, Ozkan H, Basbozkurt M. Handgun injuries with metacarpal and proximal phalangeal fractures: early definitive treatment *Int Orthop* 2008; 32: 257-62. [\[CrossRef\]](#)
7. Kostakoglu N, Kecik A. Upper limb reconstruction with reverse flaps: a review of 52 patients with emphasis on flap selection *Ann Plast Surg* 1997; 39: 381-9. [\[CrossRef\]](#)
8. Kiehn MW, Mitra A, Gutowski KA. Fracture management of civilian gunshot wounds to the hand. *Plast Reconstr Surg* 2005; 115: 478-81. [\[CrossRef\]](#)
9. Rodrigues RL, Sammer DM, Chung KC. Treatment of complex below the elbow gunshot wounds. *Ann Plast Surg* 2006; 56: 122-7. [\[CrossRef\]](#)